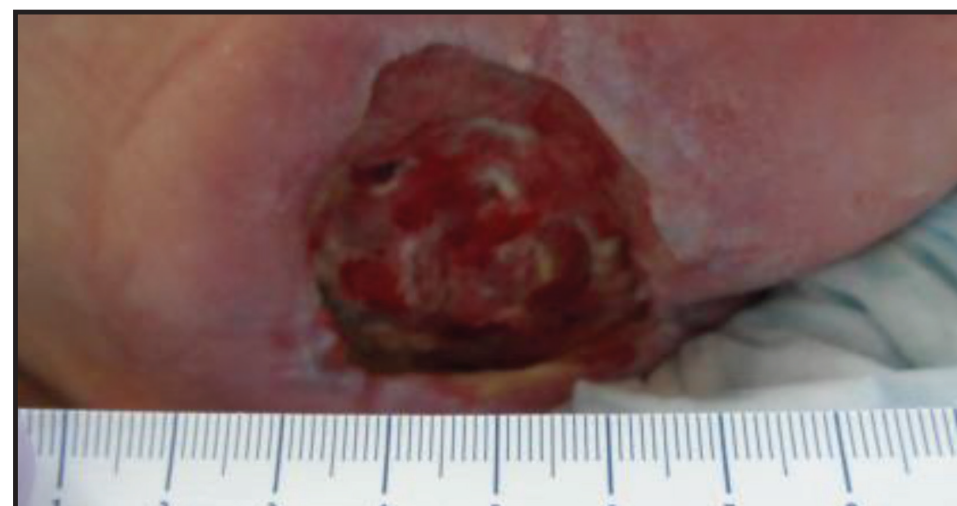


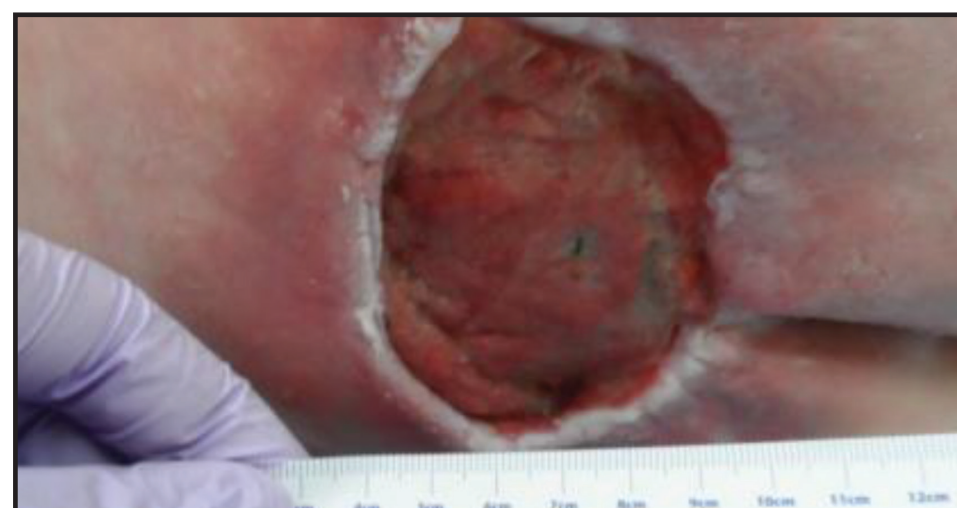Nutrition Support with an L-arginine Based Oral Nutritional Supplement is Associated with Improvement in Non-Healing Wounds

M. Huhmann^a, DCN, RD, CSO, D. Thompson^b, RN, WCC, N. Maynard^b, RN, WCC, A. LeNeave^b, RN, C. Fife^{bc}, MD, CWS, FUHM;
^a Nestle Health Science, Florham Park, NJ; ^b CHI St. Luke's Health, The Woodlands Hospital Wound Care Center; ^c Baylor College of Medicine, Houston, TX

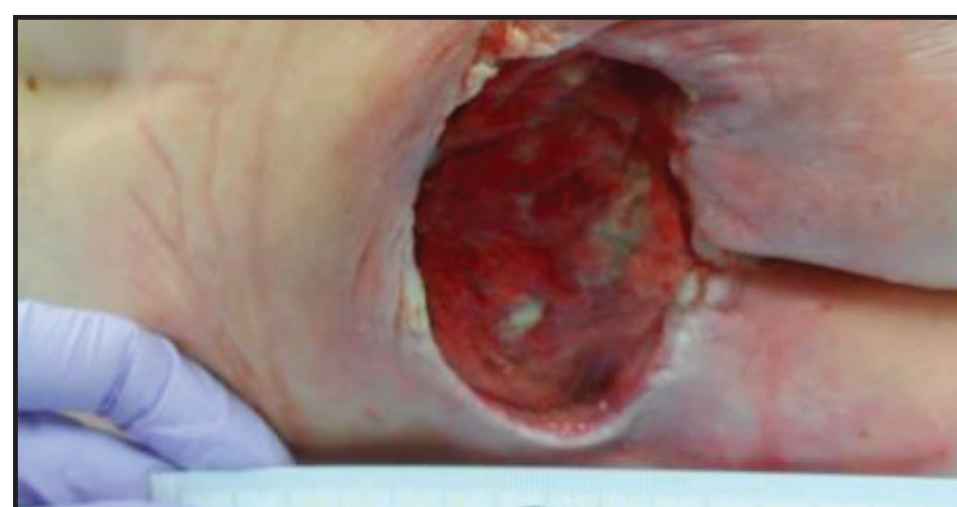SACRAL ULCER



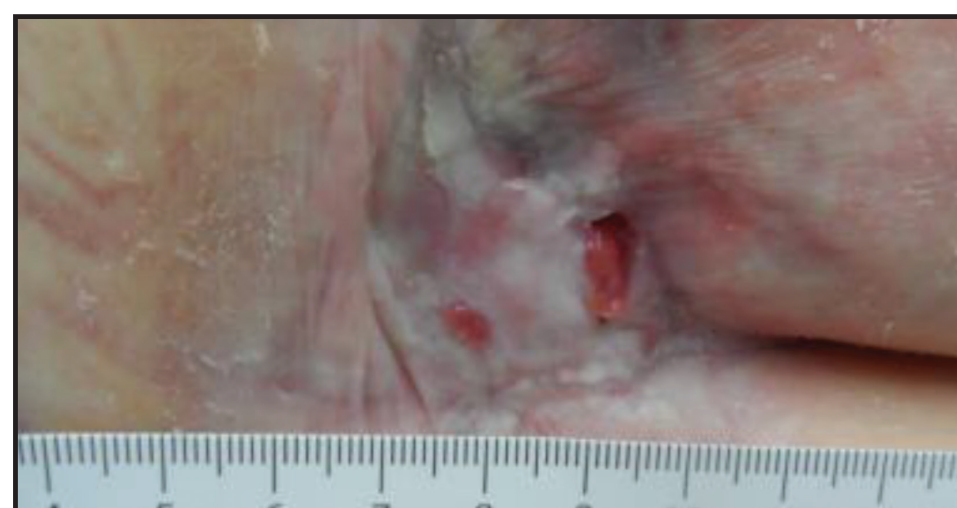January 2014
Pre-Supplementation (6cm x 6.3cm x 1.5cm)



June 2014
During supplementation with L-arginine based oral supplement (4.7cm x 7.5cm x 1.4cm)



August 2014 Supplement temporarily discontinued (6cm x 7.4cm x 1.1cm)



May 2015 (2.1cm x 1.6cm x 0.2cm)

Introduction:

Nutrition support and correction of nutritional deficiencies is critical to wound healing. Arginine, a conditionally essential amino acid, serves as a substrate for protein synthesis, and is a precursor to nitric oxide (NO) and proline production—all of which play a role in wound healing.

Case Summary (February 2014):

- 84-year old female originally presents to St Luke's The Woodlands Wound Care Clinic in August 2013
- S/P hip fx secondary to fall, DM, orthostatic hypotension
- Bed bound
- Unintentional weight loss
- Albumin: 2.3 g/dL
- Stage III Pressure Ulcer – Sacrum with exposed bone (6cm x 6.3cm x 0.2cm)
- Deep tissue injury – Right Calf (August 2014)

Nutrition Intervention:

- Documented poor oral intake—oral nutrition supplement initiated.
- Arginaid® (Nestlé Health Science, Florham Park, NJ), an L-arginine containing oral supplement, initiated December 2013.
- Patient ran out of L-arginine based supplement late June 2014 to late August 2014.
- L-arginine based supplement restarted end August 2014 due to worsening of sacral wound (6cm x 7.4 cm x 1.1 cm) and new deep tissue injury (right calf) and small lesions (feet and hands).

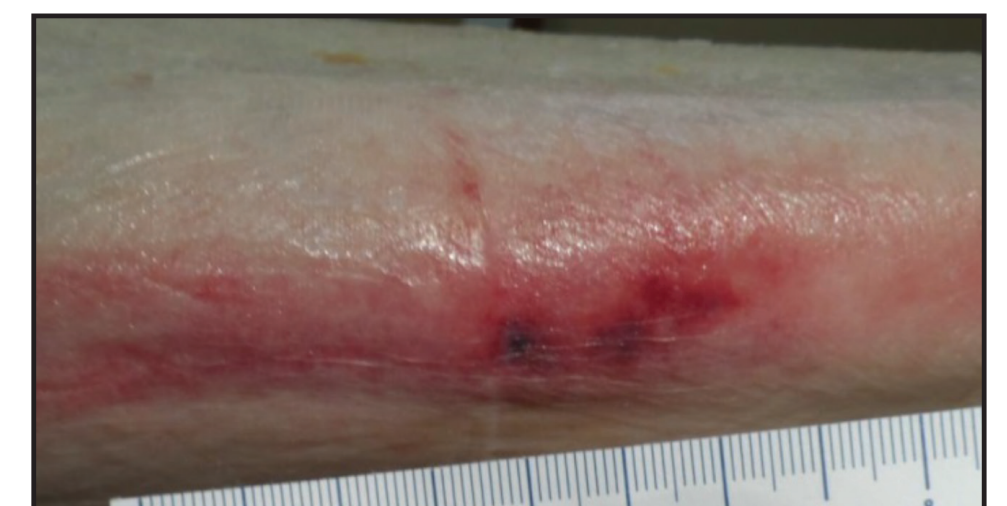Outcomes:

- Significantly improved sacral wound
- Healed leg wound

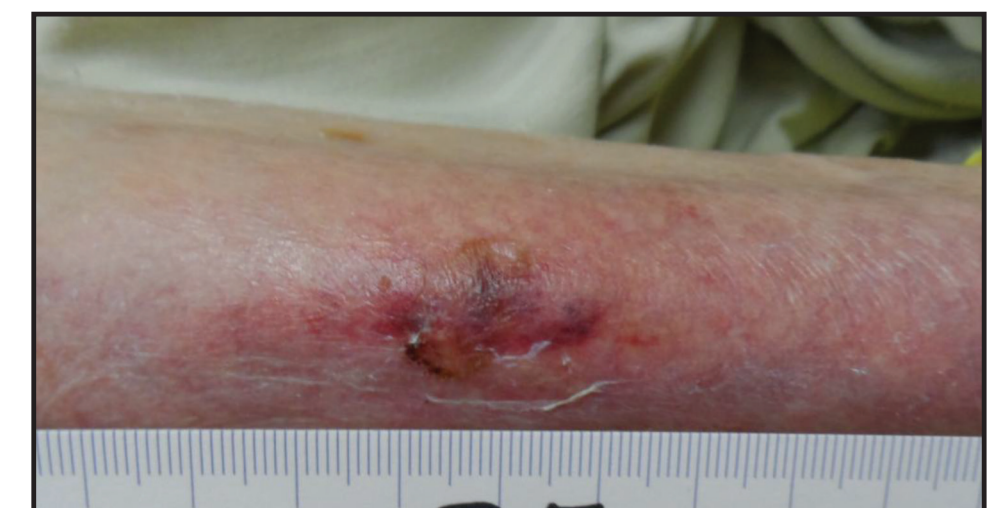Conclusions:

Nutrition support with an L-arginine containing oral supplement has a positive effect on wound healing with pressure ulcer and deep tissue wounds.

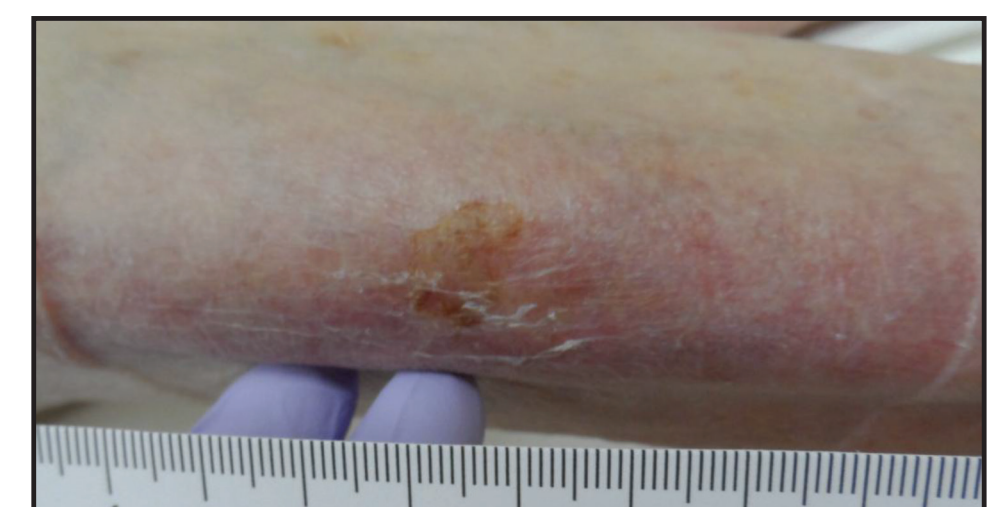RIGHT CALF ULCER



Late July 2014

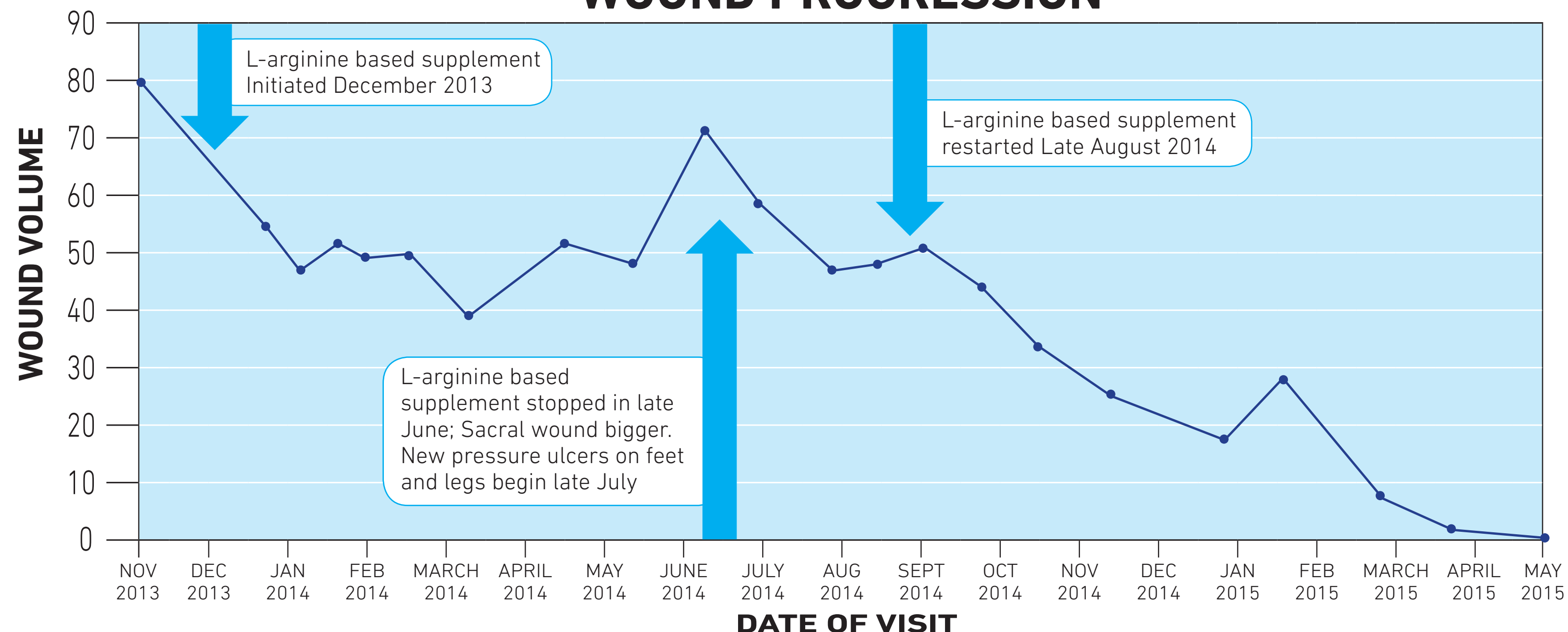


Late August 2014



September 2014

WOUND PROGRESSION



Unless otherwise noted, all trademarks are owned by Société des Produits Nestlé S.A., Vevey, Switzerland. ©2015 Nestlé. All rights reserved.